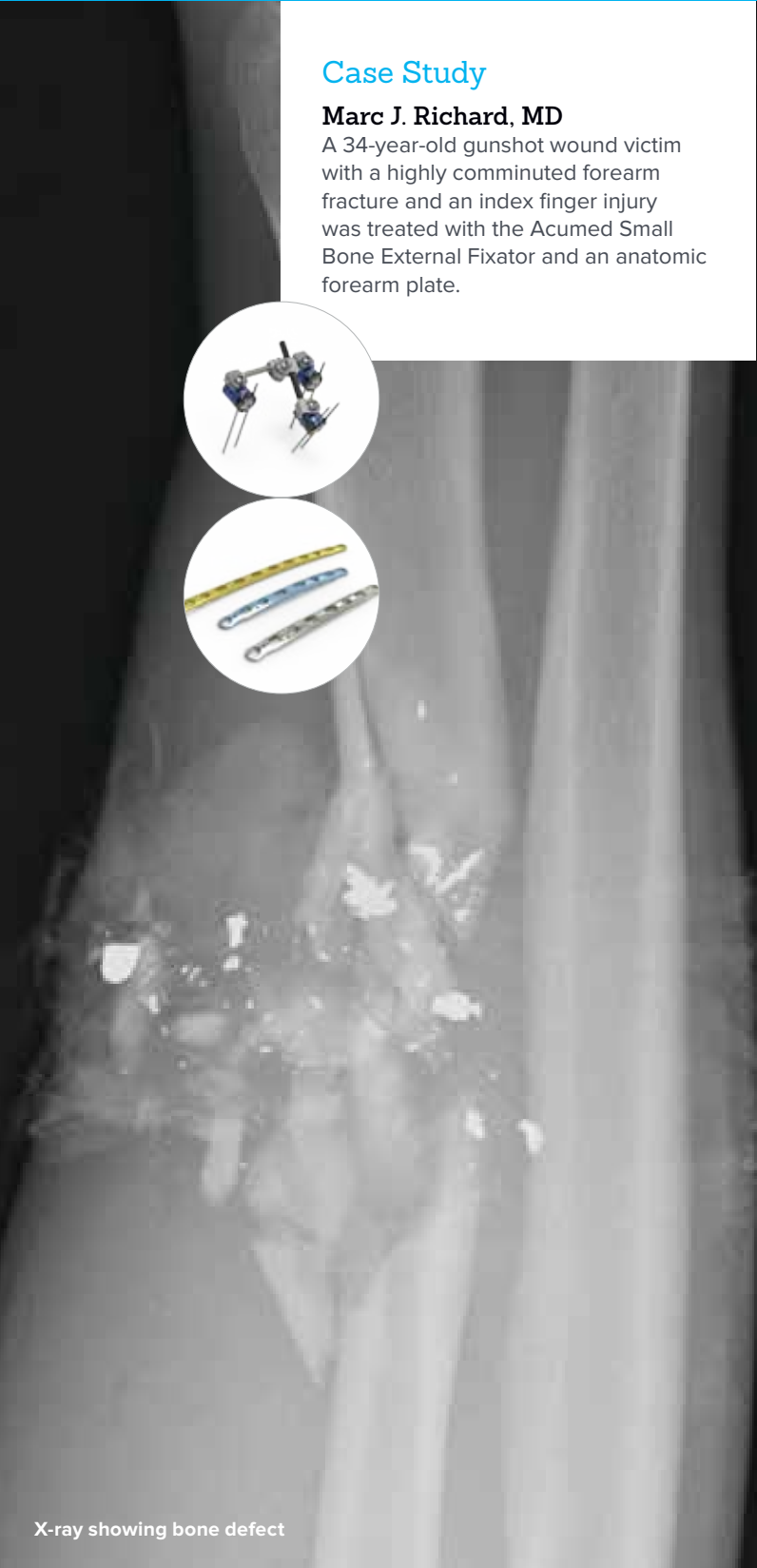



Phalangeal and Forearm Open Fractures Treatment With Internal and External Fixation

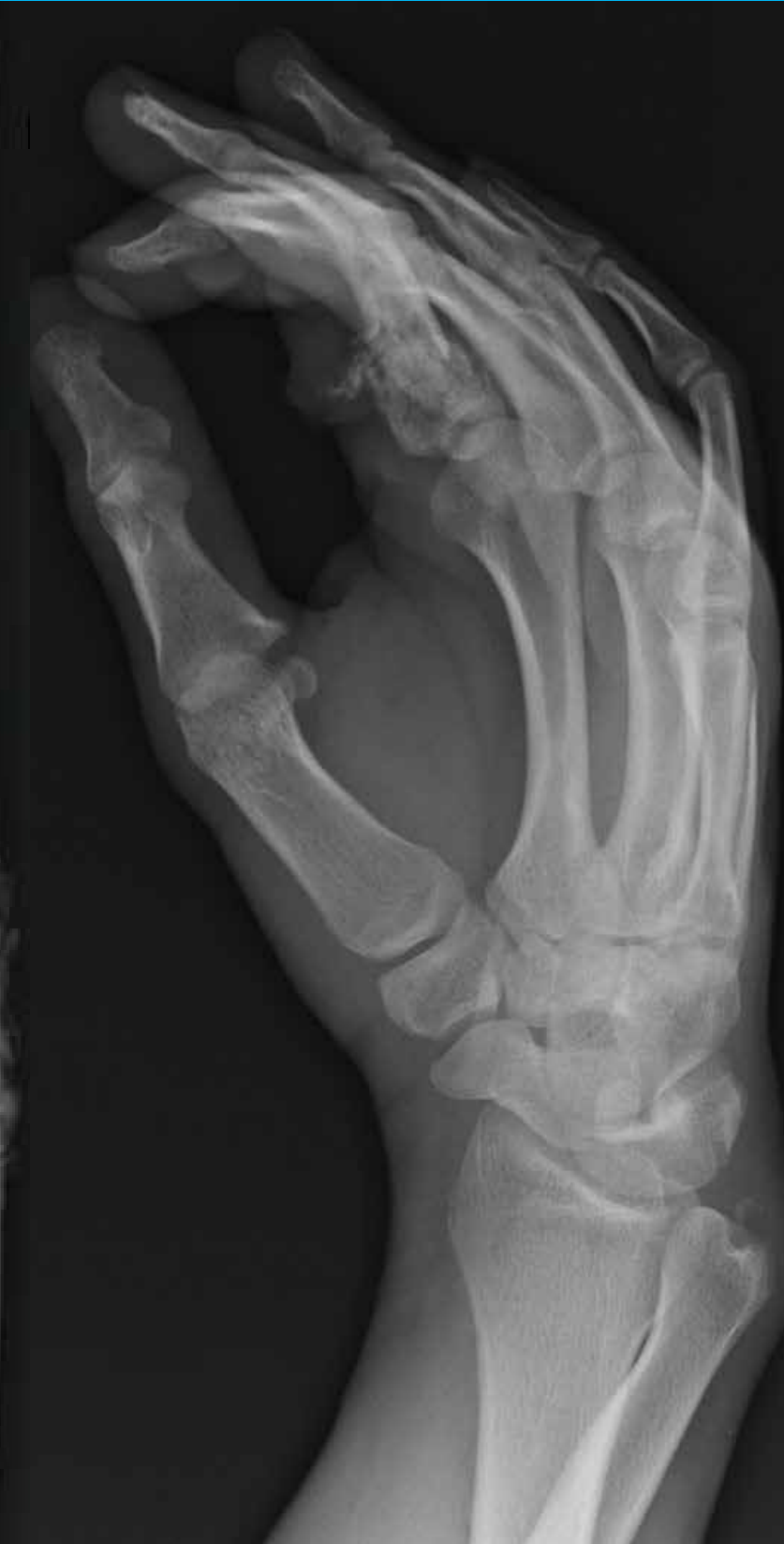Case Study

Marc J. Richard, MD

A 34-year-old gunshot wound victim with a highly comminuted forearm fracture and an index finger injury was treated with the Acumed Small Bone External Fixator and an anatomic forearm plate.



X-ray showing bone defect

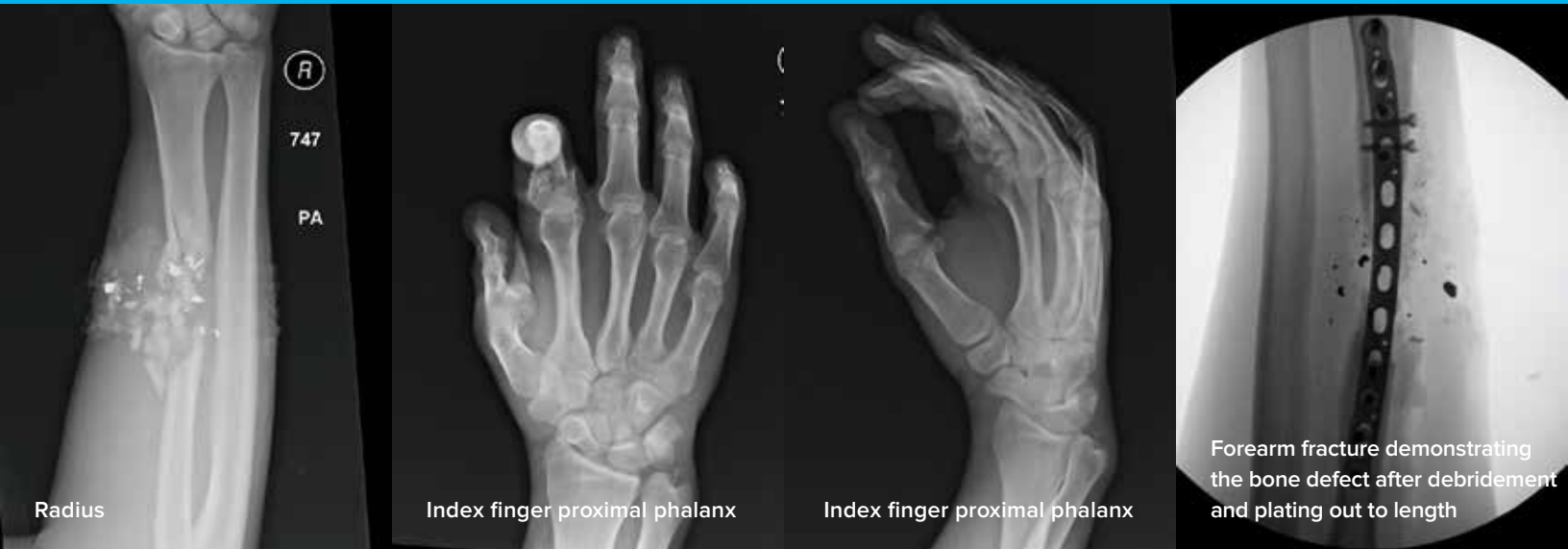

Acumed® is a global leader of innovative orthopaedic and medical solutions.



We are dedicated to developing products, service methods, and approaches that improve patient care.

Case Study | Marc J. Richard, MD



Phalangeal and Forearm Open Fractures Treatment With Internal and External Fixation

Patient History

A 34-year-old, right-hand-dominant male sustained a gunshot wound to the right forearm and index finger. He had palpable radial and ulnar pulses and immediate capillary refill in the tip of the index finger. His only neurological deficit was decreased sensation to light touch on the radial and ulnar aspects of the index finger. The patient had entrance and exit wounds on the volar and dorsal aspect of the index finger and forearm. Exam was limited by pain and concomitant injuries such that the tendon status of the index finger was not able to be evaluated. Radiographs demonstrated a highly comminuted radial shaft fracture and index finger proximal phalanx fracture. Forearm and hand compartments were soft and compressible.

Treatment

The patient was taken to the operating room for irrigation and debridement of his wounds and management of his open fractures. The patient was placed supine on the operating table with a hand table attachment. The right upper extremity was prepped and draped in the usual sterile fashion. A volar Henry approach was performed over the forearm with excision of the exit wound. A highly comminuted segment of bone measuring 4 cm in length was noted to be devoid of soft tissue attachments and was removed. An anatomic radial forearm plate was used to fix the radius out to length and a form-fitting antibiotic cement spacer was fashioned to maintain the bone defect. It was secured to the plate with embedded K-wires bent into hooks and placed through the empty plate holes.

The index finger wound edges were debrided. The volar exit wound was stellate and precluded a formal incision. Working through the traumatic wound, the neurovascular

Treatment [continued]

bundles were identified and noted to be in continuity. Similarly, the flexor tendon sheath was visualized. The ulnar aspect of the A2 pulley and 50% of the ulnar slip of flexor digitorum superficialis (FDS) were injured. The ulnar slip of FDS and the injured edges of the A2 pulley were sharply debrided. Tenodesis of the hand and wrist confirmed continuity of the flexor and extensor tendons. Fluoroscopy was used to evaluate the proximal phalanx fracture. The fracture was highly comminuted, but noted to be well aligned on orthogonal views with traction applied. Given the complexity of the comminuted fracture pattern and the tenuous soft tissue envelope, the decision was made to treat the proximal phalanx in an external fixator.

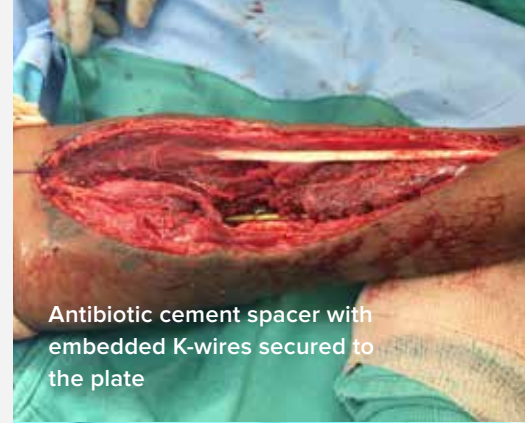The Acumed Small Bone External Fixator was applied from the index finger metacarpal to the proximal phalanx in order to bridge the comminuted fracture and soft tissue injury. The .045" x 6" single trocar guide wires were selected as the external fixation pins. K-wire position was selected by using the Pin Guide Assembly with fluoroscopic guidance to confirm that the wires would be appropriately placed outside the zone of injury. Two bicortical K-wires were placed in parallel fashion through the Pin Guide Assembly in each bone. A Small Bone Housing Assembly was placed over the metacarpal and phalangeal pins respectively. These were provisionally tightened to the pins with the hex wrench. A 60 mm and a 90 mm carbon fiber rod were placed through each rod clamp and secured to each other with a rod-to-rod clamp. Fluoroscopy was again used to confirm appropriate reduction and final tightening of the construct was performed.

Postoperative Care

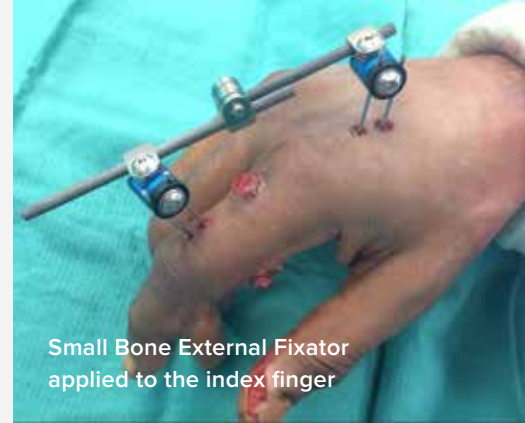The patient initiated local wound care to the volar finger wound immediately post-op. The external fixator allowed appropriate access to this soft tissue injury. He was seen in clinic on post-op day 14 for evaluation. His sutures were removed and X-rays were obtained confirming maintenance of fracture alignment. The patient was instructed on appropriate pin care by cleansing the skin using a cotton-tipped swab soaked in a 1:1 mixture of sterile water and hydrogen peroxide. He was then seen 6 weeks post-operatively at which time his soft tissues had completely healed. The timing was appropriate for the second stage of his forearm reconstruction, using the Masquelet technique. He was then taken back to the operating room for removal of the antibiotic cement spacer with autogenous iliac crest bone grafting. At the same time, the external fixator was removed from his index finger and evaluated intra-operatively for union. If there was incomplete bony union, he was consented for open reduction and internal fixation of the proximal phalanx with a plate from the Acumed Hand Fracture System. Live fluoroscopic evaluation demonstrated complete consolidation and no further surgical intervention was required. He was then enrolled in a hand therapy program for edema control and progression of range of motion. At 6 months after the initial injury, he had clinically and radiographically healed both injuries and recovered complete range of motion at the digit and the forearm. His sensory loss in the index finger was neurapraxic and also recovered over this time.

Discussion

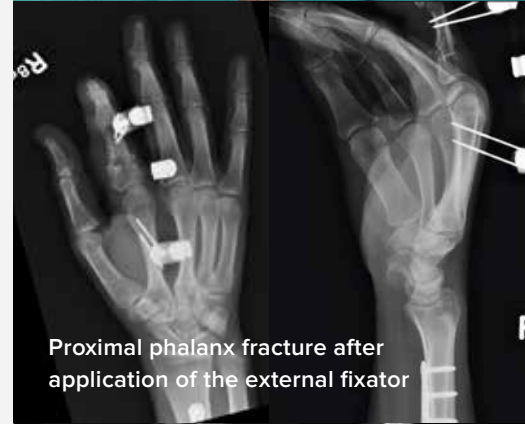Ballistic injuries are often associated with a unique pattern of injury. The bony injury typically has a large area of comminution. There is always an associated soft tissue injury with a zone of injury that is often larger than anticipated by gross inspection. A careful physical examination and intra-operative evaluation of the wound is required to appropriately manage these complex injuries. In the digit, these injuries are often ideally treated with an external fixator. The Small Bone Fixator allows for access to the associated soft tissue injury for concomitant management. These ballistic injuries also typically result in a highly comminuted fracture pattern that limits the ability to perform open reduction and internal fixation. External fixation allows for consolidation of these fragments without the need for fragment-specific fixation. In cases where complete union is not achieved by this mode of fixation, revision of internal fixation is significantly easier because the large number of comminuted fragments consolidate and only one nonunion site remains.



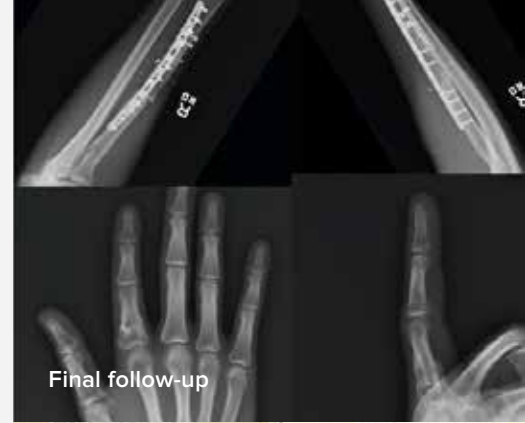Antibiotic cement spacer with embedded K-wires secured to the plate



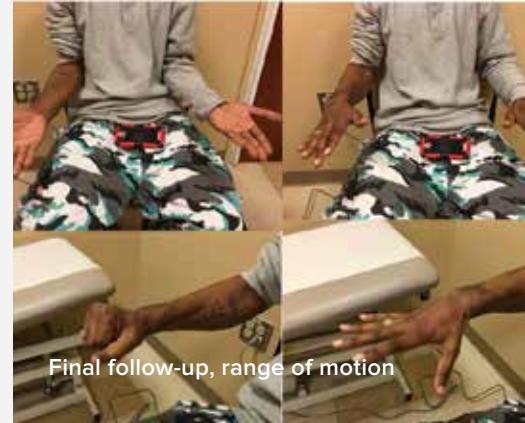Small Bone External Fixator applied to the index finger



Proximal phalanx fracture after application of the external fixator



Final follow-up



Final follow-up, range of motion



HNW70-09-B

Effective: 2017/02

© 2017 Acumed® LLC

Acumed® Headquarters
5885 NW Cornelius Pass Road
Hillsboro, OR 97124
Office: 888.627.9957
Fax: 503.520.9618
www.acumed.net

These materials contain information about products that may or may not be available in any particular country or may be available under different trademarks in different countries. The products may be approved or cleared by governmental regulatory organizations for sale or use with different indications or restrictions in different countries. Products may not be approved for use in all countries. Nothing contained on these materials should be construed as a promotion or solicitation for any product or for the use of any product in a particular way which is not authorized under the laws and regulations of the country where the reader is located. Specific questions physicians may have about the availability and use of the products described on these materials should be directed to their particular local sales representative. Specific questions patients may have about the use of the products described in these materials or the appropriateness for their own conditions should be directed to their own physician.

